

# The Downside of Spatial Normalisation in fMRI of Medial Temporal Lobe Structures

M. Liptrot<sup>1</sup>, T. Ramsøy<sup>1</sup>, T. Lund<sup>1</sup>, K. Sidaros<sup>1</sup>, M. Christensen<sup>1</sup>, F. Nielsen<sup>2,3</sup>, W. Baare<sup>1</sup>, T. Jernigan<sup>1,4</sup>

<sup>1</sup>Danish Research Centre for Magnetic Resonance, Copenhagen University Hospital, Hvidovre, Hvidovre, Copenhagen, Denmark, <sup>2</sup>Neurobiology Research Unit, Copenhagen University Hospital, Hvidovre, Copenhagen, Copenhagen, Denmark, <sup>3</sup>Informatics and Mathematical Modelling, Technical University of Denmark, Lyngby, Copenhagen, Denmark, <sup>4</sup>Laboratory of Cognitive Imaging, UCSD, San Diego, California, United States

**Introduction:** The study of deep structures within the brain, such as the medial temporal lobe (MTL), is attracting increased interest due to its link with various degenerative disorders, including Alzheimer's disease (AD). In particular, evidence of damage to the perirhinal cortex (PrC) early in the course of the disease has been reported [1]. Previous studies of the PrC in both monkeys [2] and humans [3-5] have been used to develop functional paradigms that are directed primarily at PrC activation [6] with the aim of highlighting pre-clinical changes. Functional imaging of such structures requires optimised acquisition protocols to minimize EPI distortions. However, there remains the question of inter-subject variance, both functionally and anatomically, and investigation of their extent is essential before group analysis via spatial normalisation is performed.

**Objective:** To investigate the degree of functional and anatomical variance in MTL structures and their impact upon group analysis after spatial normalisation.

**Method:** MTL regions of 13 healthy subjects (9 female, mean age 28, 12 right-handed, 1 left-handed) were scanned using BOLD fMRI in a Siemens Magnetom Trio 3T with a GE-EPI sequence optimized for the MTL structures (TR=2000ms, TE=30ms, 64x64 matrix, 3x3x2mm) [8]. The SPM2 package (<http://www.fil.ion.ucl.ac.uk/spm>) was used for most of the pre-processing and analysis steps. The activation paradigm [6] consisted of two tasks, encoding either objects (OE) or their position (PE). Statistical analysis was performed using a general linear model with RETROICOR (respiration and heartbeat) and expanded motion parameters as nuisance regressors [7]. Significant PrC activations were determined in native space using the Insausti protocol [9]. Group analysis (random effects) was performed in MNI space after spatial normalisation (SPM2, 12 parameters, no smoothing). For comparison, the native-space peak activations were also transformed into the common MNI space. Additionally, anatomical ROIs of MTL structures (including entorhinal cortex, perirhinal cortex, hippocampus, parahippocampal cortex) were hand-drawn on each subject's structural scan (3D-T1W MPRAGE) using 'DISPLAY' (<http://www.bic.mni.mcgill.ca/>) according to the Insausti protocol [9], by a single, trained expert (TZR). Spatial normalisation of these ROIs was also performed, and their co-localisation investigated via the Brede Toolbox [10].

**Results:** *Native space analysis:* The OE>PE contrast gave significant activation in the left PrC of 10 subjects ( $p < 0.05$ , FDR, voxel threshold = 5), and in the right PrC only for a single subject. Around half the subjects exhibited bilateral activation. Only one subject had no significant PrC activity. *Spatially-normalised analysis:* Group analysis in MNI space resulted in an activation peak in the left posterior PrC. Significant results at  $p < 0.05$  (FDR, cluster threshold=5) included bilateral hippocampus, left amygdala, left fusiform gyrus, left lingual gyrus and left cuneus. When the native-space activations were mapped into MNI space, several PrC peaks came to lie outside the MNI PrC and ended-up within neighbouring structures (Fig 1). Additionally, when the anatomical ROIs were normalised, it was clear that the PrC structure incurs a great degree of variability of size, shape and location within MNI space (Fig 2). These results highlight the problem facing the interpretation of a group analysis when the underlying structural basis of the generating activations is unclear, and hence indicates how critical it is to take them into consideration.

**Conclusion:** Our previous study [6] has demonstrated that activation of the PrC is feasible, reliable, sensitive and robust enough to be used in the search for pre-clinical changes of AD in native space. However to achieve clinical utility, a pre-defined area is required in which the hypothesis of functional damage can be applied. We have shown that the standard methods applied in such cases are insufficient for the MTL structures, even with optimised acquisition sequences. Hence either a far more advanced spatial normalisation approach, or a method of extracting the determining features from the native space, is required in order to be able to perform a reliable group analysis. We are now focussing on the development and comparison of both solutions for use in a large upcoming study of AD.

## References:

- [1] Braak H, Braak E. (1996) Acta Neurol Scand Suppl. 165:3-12
- [2] Baxter M.G. & Murray E.A. (2001) Hippocampus 11, 61-71.
- [3] Pihlajamaki M. et al. (2004) Eur J Neurosci. 19(7):1939-49.
- [4] Reber PJ, Wong EC, Buxton RB (2002) Hippocampus 12(3):363-76
- [5] Davachi L, Mitchell JP, Wagner AD (2003) Proc Natl Acad Sci U S A. 18;100(4):2157-62
- [6] Ramsøy TZ, et al. Human Brain Mapping 2005
- [7] Lund T. et al. Neuroimage (2005). In press. doi:10.1016/j.neuroimage.2005.07.005.
- [8] Deichmann R, Gottfried JA, Hutton C, Turner R. (2003) Neuroimage 19(2 Pt 1):430-41
- [9] Insausti R, et al. (1998) AJNR Am J Neuroradiol 19(4):659-71.
- [10] Nielsen FA, Hansen LK (2000) In Klasky S & Thorpe S, VDE2000, Workshop Proceedings.

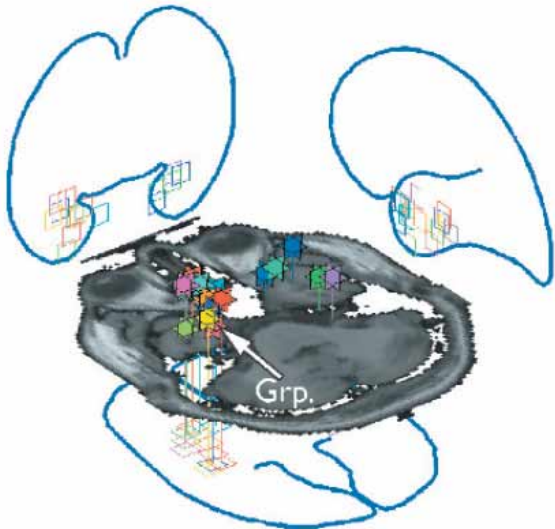


Figure 1: Brede visualization of the native-space PrC activation peaks mapped into MNI space. Note how several of the peaks end-up outside the PrC. "Grp" indicates the result from the group analysis of the data after spatial normalisation.

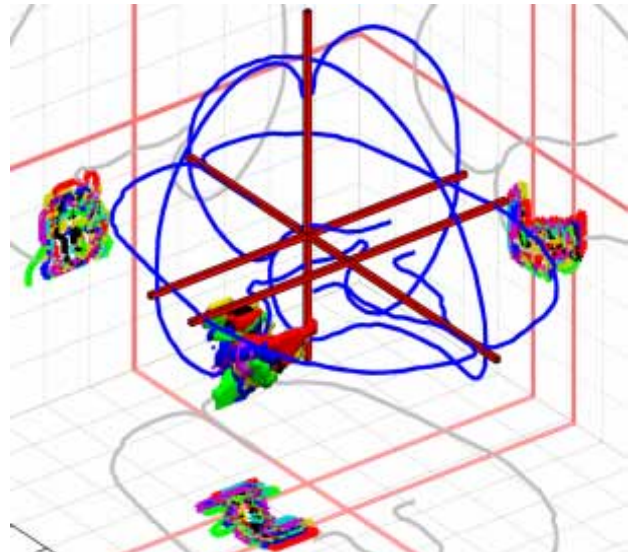


Figure 2: Brede visualization of the anatomical left PrC ROIs from 6 subjects (limited number for clarity). Note the large variation in shape, size and location of the different subjects' ROIs when mapped to the common MNI space.